

12

AUTOPSY REPORT

No.
2020-00797

DOE, JOHN
(LATER IDENTIFIED AS)
BRYANT, KOBE BEAN

I performed an autopsy on the body of →

at the DEPARTMENT OF MEDICAL EXAMINER-CORONER

Los Angeles, California on JANUARY 28, 2020 0930 HOURS

(Date)

(Time)

From the anatomic findings and pertinent history I ascribe the death to:

(A) BLUNT TRAUMA

DUE TO OR AS A CONSEQUENCE OF

(B)

DUE TO OR AS A CONSEQUENCE OF

(C)

DUE TO OR AS A CONSEQUENCE OF

(D)

OTHER CONDITIONS CONTRIBUTING BUT NOT RELATED TO THE IMMEDIATE CAUSE OF DEATH

MANNER OF DEATH

ACCIDENT

HOW INJURY OCCURRED

COMMERCIAL HELICOPTER CRASH, PASSENGER

Anatomic Summary:

- I. Blunt trauma, fatal.
 - A. Blunt trauma of head.
 - 1. Multiple lacerations of face, scalp, and neck.
 - 2. Multiple fractures of skull and face.
 - 3. Evisceration of brain.
 - B. Blunt trauma of chest and abdomen.
 - 1. Traumatic injuries of neck, left shoulder, and lower abdomen.
 - 2. Multiple fractures of ribs, spine, and hips.
 - 3. Evisceration of internal organs.
 - C. Blunt trauma of extremities.
 - A. Multiple fractures of left arm.
 - B. Traumatic amputation of right arm.
 - 1. Right forearm and hand submitted separately.
 - C. Multiple fractures of the femurs.
 - D. Traumatic amputation of lower extremities.
 - 1. Both feet recovered.
- II. Postmortem burns.
 - A. Extensively burned skin of head, chest, and abdomen.
 - B. 30% total body surface area burns.
 - C. No soot in trachea or bronchi.

12**AUTOPSY REPORT**

No.

2020-00797

BRYANT, KOBE BEAN

Page 2

III. Toxicology Report.
A. Methylphenidate present.

Decedent is a 41-year-old Black male who on 1/26/2020 was a passenger in a commercial helicopter that crashed into the mountain side in the city of Calabasas. He was pronounced dead at the scene on 1/26/2020 at 1010 hours.

EVIDENCE OF INJURY:

Blunt trauma.

Blunt trauma of head. Examination of the head reveals a flattened but generally intact face and scalp. There is a 6 x 5 inch laceration of the frontal scalp involving the right eye exposing the cranial vault. No brain matter is identified. The left eye is present and appears to be brown in color with congested hemorrhagic sclera. The left lower chin shows a 6 x 6 inch laceration exposing the tongue and multiple fractured segments of mandible. Those fragments contained intact teeth. Examination of the occipital aspect of the scalp reveals a 6 x 4-1/2 inch laceration involving the mid to left aspect of the scalp. There's also a laceration noted to the right superior parietal scalp. The neck area is exposed showing a segment of the cervical spine. The hyoid bone and thyroid cartilage show multiple fractures.

BLUNT TRAUMA OF CHEST AND ABDOMEN:

Examination of the skin reveals a large laceration involving the anterior neck, upward chest, and left shoulder area. The chest cavity is visible through this defect. A 1-1/2 x 1 inch laceration is noted to the right lateral lower chest. The skin is torn below the pubic region and anteriorly and extends circumferentially toward the back just superior to the buttocks. Both clavicles, the entire rib cage, pelvis, and lumbar and sacral spine show fractures.

12**AUTOPSY REPORT**

No.

2020-00797

BRYANT, KOBE BEAN

Page 3**BLUNT TRAUMA OF EXTREMITES:**

The left arm is attached and contains multiple fractures of the humerus, radius, and ulna. Lacerations are noted to the axillary region and mid upper arm. Examination of the hand reveals a laceration to the palmer aspect of the hand as well as dorsal aspect of the hand. There is avulsion of the 4th fingernail. There is traumatic amputation of the right arm. Submitted separately is the right forearm. The dorsal aspect shows a compound (open) fracture of the radius. The amputation site shows ragged skin and exposed muscle along with fragments of radius and ulna. Skin slippage is noted to the dorsal of the right hand. The ventral aspect shows a 2-1/2 inch laceration at the base of the thumb. Multiple tattoos are identified from the ventral aspect of the forearm. Examination of the lower extremities shows complete disruption of anatomic structures resulting in a fragmentation of muscle, tendon, and skin. A right femoral head is identified but no femoral condyle. The left femoral neck and hip is identified. A distal fragment of femur with condyle is noted. There appears to be a fracture of the lateral condyle. No feet are attached to the body. They are traumatically amputated above the ankle. Two feet present, are present inside multicolored court shoes. They are identified by shoe size. An amorphous mass of soft tissue is identified via DNA analysis as belonging to Kobe Bean Bryant.

POSTMORTEM BURNS:

Examination of the skin reveals extensive burning of the left temporal parietal scalp as well as right superior parietal scalp and right occipital scalp. The entire anterior chest shows extensive burning as well as a segment of the left lateral arm and hand. Examination of the back reveals focal areas of extensively burned skin involving the right midback and lower back. In aggregate it amounts to approximately 30% total body surface area burns.

12**AUTOPSY REPORT**

No.

2020-00797

BRYANT, KOBE BEAN

Page 4**EXTERNAL EXAMINATION:**

The body is identified by toe tags and is that of an unembalmed Black male. The entirety of the body measures 65 inches which obviously does not reflect the original height of the body. The total weight of the body is 178 pounds. There is a partial tattoo noted to the right upper arm which is disrupted by the traumatic amputation and reveals what appears to be a segment of butterfly which is part of a crown and radiating dark lines expanding from the crown. Examination of the right forearm shows multiple tattoos which include the name "Bianka", below that is the word "Bella", below that is the name "Gianna", below that is the name "Maria-Onore", below that is the word "Natalia", and below that is the word "Diamante". Below that is a diamond. A mustache is noted to the upper lip. The left eye is brown and hemorrhagic. Lower teeth are present amongst the fractured mandible. The penis is identified and is circumcised but shows traumatic degloving.

EVIDENCE OF THERAPUTIC INTERVENTION:

None. There has not been postmortem intervention for procurement.

CLOTHING:

The body was not clothed but I did examine the clothing and it consists of the following: There are 7 items of clothing. Each shows tearing artifact and some show burned artifact and each has a strong odor of fuel. Of the 7 items only 2 are recognizable. One is a pair of underwear with the elastic band that reads Calvin Klein and the other is a pair of black pants with an elastic waist.

12**AUTOPSY REPORT**

No.

2020-00797

BRYANT, KOBE BEAN

Page 5**INITIAL INCISION:**

The body cavities are entered through the standard coronal incision. The chest and abdominal cavities are empty secondary to traumatic evisceration. The entire rib cage is disrupted with multiple fractures of the cervical thoracic lumbar and sacral spine.

SYSTEMIC AND ORGAN REVIEW

The following observations are limited to findings other than injuries which have been described above.

Note: Minimal organs are recovered and only those will be described.

CARDIOVASCULAR SYSTEM:

Two fragments of heart muscle are identified weighing in at aggregate 175 grams. Papillary musculature is identified, however, no other structures are noted.

RESPIRATORY SYSTEM:

No soot is found in the upper respiratory or lower bronchial passages. A nearly intact left lung is identified which weighs 330 grams. A segment of right lung is attached to a bronchi and that segment weighs 75 grams. The parenchyma of both lung segments show hemorrhage.

GASTROINTESTINAL SYSTEM:

A 200 cm segment of small and large bowel is recovered. Soft green stool is noted in the colon. The small bowel contents are minimal. No appendix is identified in any of the bowel segments.

12**AUTOPSY REPORT**

No.

2020-00797

BRYANT, KOBE BEAN

Page 6

HEPATOBIILIARY SYSTEM:

A fragmented liver is recovered. This fragment weighs 200 grams. An attached gall bladder is noted which contains 1 cc of bile. This bile is collected.

URINARY SYSTEM:

A single kidney which has been fragmented into three separate parts is collected. It weighs 120 grams. No other identifiable organs are identified.

HISTOLOGIC SECTIONS:

Representative sections of various organs are preserved in one storage jar in 10% formalin.

TOXICOLOGY:

Bile, liver tissue, and vitreous humor have been submitted to the lab. A comprehensive screen was requested.

PHOTOGRAPHY:

Photographs have been taken prior to and during the course of the autopsy.

RADIOLOGY:

The body was fluoroscoped and x-rays are taken of the head, chest, and extremities. X-rays reveal multiple fragmented bone involving the entire body.

WITNESSES:

None.

12**AUTOPSY REPORT**

No.

2020-00797

BRYANT, KOBE BEAN


Page 7

DIAGRAMS USED:

Diagram Form 20 and 43 were used during the performance of the autopsy. The diagrams are not intended to be facsimiles.

OPINION:

The cause of death of this 41 year old Black male identified as Kobe Bean Bryant, is due to blunt trauma. These injuries are rapidly if not instantly fatal. Thermal burns present on the head, chest, and extremities are postmortem and did not contribute to death. The manner of death is deemed accident.



JUAN M. CARRILLO, M.D.
SENIOR DEPUTY MEDICAL EXAMINER

DATE

4-30-20

JMC:qeb

D: 01/28/2020 13:14:00

T: 01/31/2020 09:28:00

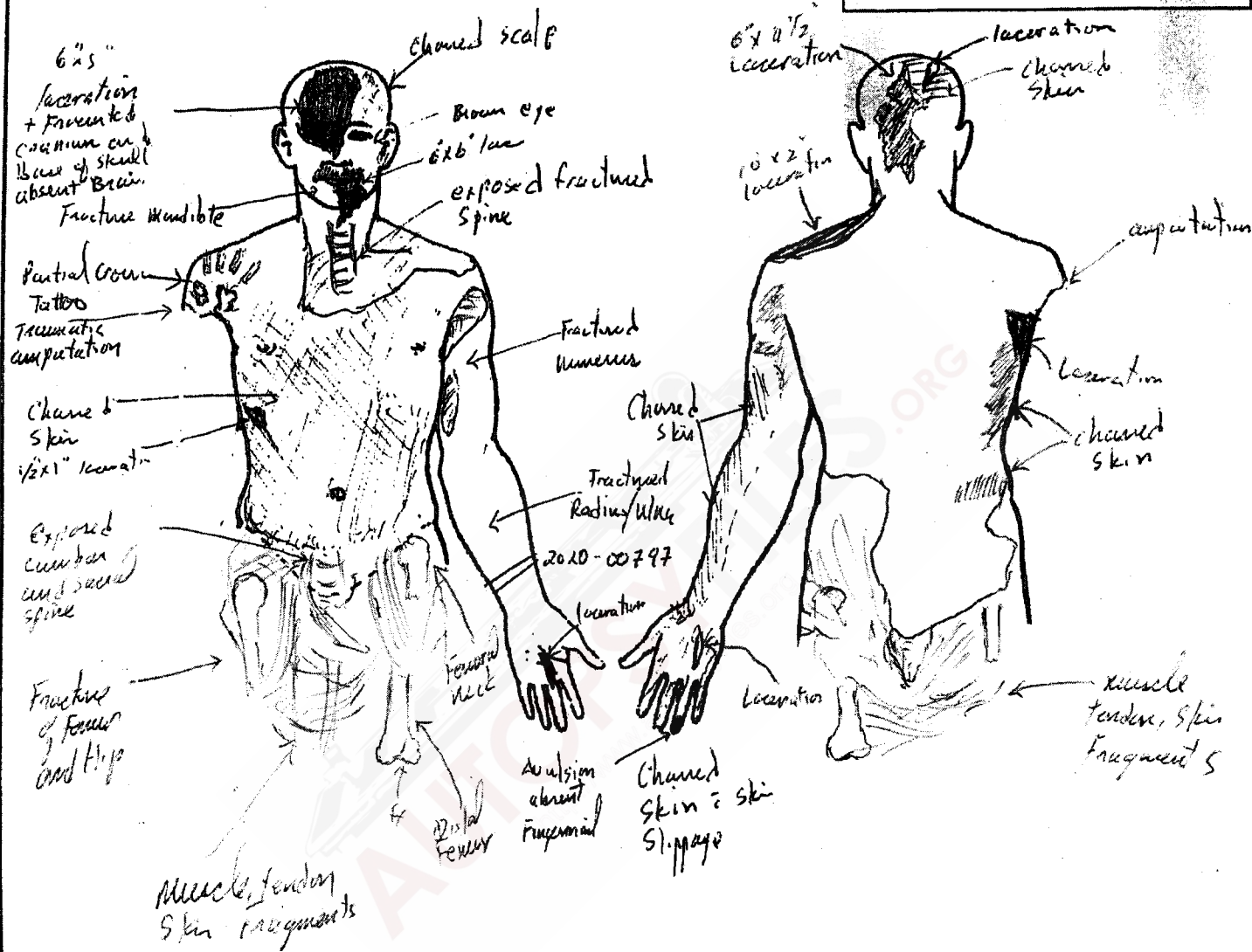
20

2020-00797

BRYANT, KOBE BEAN

ACC

SEC



Right Thumbprint

Date JAN 28 2020

JUAN CARRILLO, M.D.

M.D.

Deputy Medical Examiner

COUNTY OF LOS ANGELES

DEPARTMENT OF CORONER

43

MISCELLANEOUS WORK SHEET

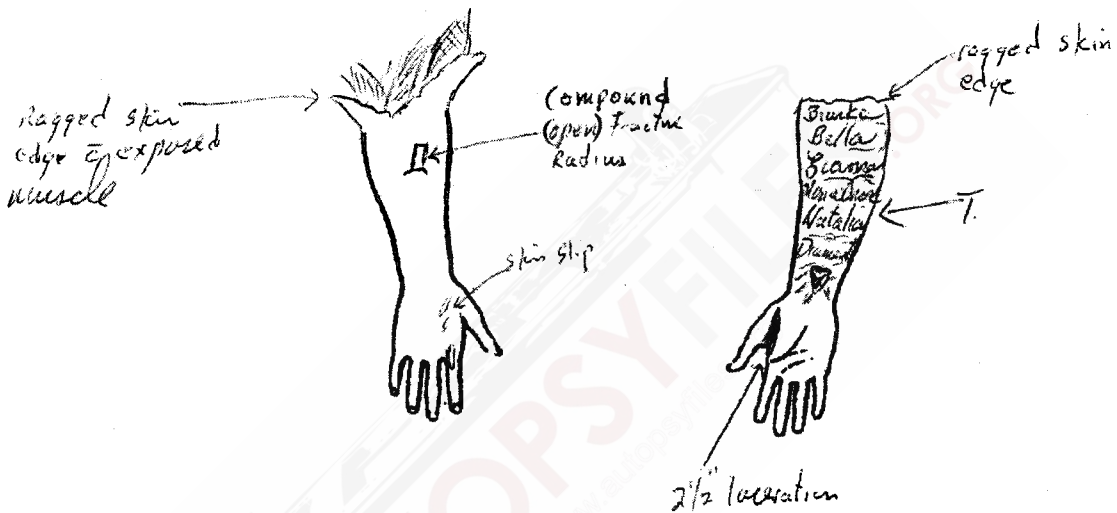
2020-00797

BRYANT, KOBE BEAN

ACC

SEC

traumatic amputation
of right arm



Date JAN 28 2020

JUAN CARRILLO, M.D.

M.D.

Deputy Medical Examiner

MEDICAL REPORT

COUNTY OF LOS ANGELES

DEPARTMENT OF MEDICAL EXAMINER-CORONER

15

AUTOPSY CLASS: A B C Examination Only D

FAMILY OBJECTION TO AUTOPSY

Date: 1/28/20 Time: 9:30 Dr. *Cumby*
(Print)

FINAL ON: 1/28/20 By: *Cumby*
(Print)

APPROXIMATE INTERVAL BETWEEN ONSET AND DEATH

2020-00797

BRYANT, KOBE BEAN

ACC

SEC

DEATH WAS CAUSED BY: (Enter only one cause per line for A, B, C, and D)

IMMEDIATE CAUSE:

(A) *Blunt Trauma*

Rapid

DUE TO, OR AS A CONSEQUENCE OF:

(B)

DUE TO, OR AS A CONSEQUENCE OF:

(C)

DUE TO, OR AS A CONSEQUENCE OF:

(D)

OTHER CONDITIONS CONTRIBUTING BUT NOT RELATED TO THE IMMEDIATE CAUSE OF DEATH:

Age: _____ Gender: Male / Female

PRIOR EXAMINATION REVIEW BY DME

BODY TAG CLOTHING
 X-RAY (No. *28*) FLUORO
 SPECIAL PROCESSING TAG MED. RECORDS
 AT SCENE PHOTOS (No. _____)

CASE CIRCUMSTANCES

EMBALMED
 DECOMPOSED
 > 24 HRS IN HOSPITAL
 OTHER: _____ (Reason)

TYPING SPECIMEN

TYPING SPECIMEN TAKEN BY: *P. Nguyen*
SOURCE: *muscle*

TOXICOLOGY SPECIMEN

COLLECTED BY: *P. Nguyen*
 HEART BLOOD STOMACH CONTENTS
 FEMORAL BLOOD VITREOUS
TECHNIQUE:
 _____ BLOOD SPLEEN
 _____ BLOOD KIDNEY
 BILE _____
 LIVER _____
 URINE _____

URINE GLUCOSE DIPSTICK RESULT: 4+ 3+ 2+ 1+ 0
TOX SPECIMEN RECONCILIATION BY: _____

HISTOLOGY

Regular (No. *1*) Oversize (No. _____)
Histopath Cut: Autopsy Lab

TOXICOLOGY REQUESTS

FORM 3A: YES NO
 NO TOXICOLOGY REQUESTED
SCREEN C H T S D
 ALCOHOL ONLY
 CARBON MONOXIDE
 OTHER (Specify drug and tissue)
THC

REQUESTED MATERIAL ON PENDING CASES

POLICE REPORT MED HISTORY
 TOX FOR COD HISTOLOGY
 TOX FOR R/O INVESTIGATIONS
 MICROBIOLOGY EYE PATH. CONS.
 RADIOLOGY CONS.
 CONSULT ON:
 BRAIN SUBMITTED
 NEURO CONSULT DME TO CUT
 CRIMINALISTICS
 GSR SEXUAL ASSAULT OTHER

NATURAL SUICIDE HOMICIDE
 ACCIDENT COULD NOT BE DETERMINED

If other than natural causes,
HOW DID INJURY OCCUR? *commercial helicopter
crash, passenger*

WAS OPERATION PERFORMED FOR ANY CONDITION STATED ABOVE: YES NO

TYPE OF SURGERY: _____ DATE: _____

ORGAN PROCUREMENT TECHNICIAN: *P. Nguyen*
PREGNANCY IN LAST YEAR YES NO UNK NOT APPLICABLE

WITNESS TO AUTOPSY EVIDENCE RECOVERED AT AUTOPSY
Item Description:

RESIDENT

DME *[Signature]*

16

2020-00797

BRYANT, KOBE BEAN
ACC

SEC

EXTERNAL EXAM

- Sex
- Race
- Age
- Height
- Weight
- Hair
- Eyes
- Sclera
- Teeth
- Mouth
- Tongue
- Nose
- Chest
- Breasts
- Abdomen
- Scar
- Genitals
- Edema
- Skin
- Decubitus

HEART Wt. 175

- Pericardium
- Hypertrophy
- Dilation
- Muscle
- Valves
- Coronaries

AORTA

VESSELS:

LUNGS Wt.

- R 75
- L 330
- Adhesions
- Fluid
- Atelectasis
- Oedema
- Congestion
- Consolidation
- Bronchi
- Nodes

PHARYNX

TRACHEA

THYROID + Fx

THYMUS

LARYNX

HYOID + Fx

ABDOMINAL WALL FAT

PERITONEUM

- Fluid
- Adhesions

LIVER Wt. 200 gm + Fragmentation

- Capsule
- Lobules
- Fibros
- G B ✓ 1cc bile
- Calculus
- Bile ducts

SPLEEN Wt.

- Color
- Consistency
- Capsule
- Malpiment

PANCREAS

ADRENALS

KIDNEYS Wt.

- R } + laceration
- L } 120 gm
- Capsule
- Cortex
- Vessels
- Pelvis
- Ureters

BLADDER

GENITALIA

- Prostate
- Testes
- Uterus
- Tubes
- Ovaries

OESOPHAGUS

STOMACH

- Contents

DUOD. & SM. INT.

APPENDIX

LARGE INT. - 200 cm of small/large bowel present

ABDOM. NODES

SKELETON

- Spine
- Marrow
- Rib Cage
- Long bones
- Pelvis

SCALP

CALVARIUM

BRAIN Wt.

- Dura
- Fluid
- Ventricles
- Vessels
- Middle ears
- Other

PITUITARY

SPINAL CORD + Fx's

TOXICOLOGY SPECIMENS

Bile, Liver, vitreous

SECTIONS FOR HISTOPATHOLOGY

MICROBIOLOGY

DIAGRAMS
X-RAYS 28

OTHER PROCEDURES

GROSS IMPRESSIONS

Blunt Trauma

Date JAN 28 2020

Time 09:30

Deputy Medical Examiner
JUAN CARRILLO, M.D.



Department of Medical Examiner-Coroner, County of Los Angeles

FORENSIC SCIENCE LABORATORIES

1104 North Mission Road, Los Angeles, CA 90033



Laboratory Analysis Summary Report

Carrillo, Juan M.D.Deputy Medical Examiner
1104 North Mission Road
Los Angeles, CA 90033 PendingTox

Coroner Case Number: 2020-00797 Decedent: BRYANT, KOBE BEAN

<u>SPECIMEN</u>	<u>SERVICE</u>	<u>DRUG</u>	<u>RESULT</u>	<u>ANALYST</u>
-----------------	----------------	-------------	---------------	----------------

Alcohol Quantitation/Confirmation

Vitreous

Alcohol-GC/FID-HS	Ethanol	* Negative	C. Castellino
-------------------	---------	------------	---------------

Drug Screen

Liver

ELISA-Immunoassay	Benzodiazepines	ND	J. Posada
ELISA-Immunoassay	Cocaine and Metabolites	ND	J. Posada
ELISA-Immunoassay	Fentanyl	ND	J. Posada
ELISA-Immunoassay	Marijuana: 11-nor-Delta-9-Carboxy-THC	ND	J. Posada
ELISA-Immunoassay	Methamphetamine & MDMA	ND	J. Posada
ELISA-Immunoassay	Opiates: Codeine & Morphine	ND	J. Posada
ELISA-Immunoassay	Opiates: Hydrocodone & Hydromorphone	ND	J. Posada
ELISA-Immunoassay	Phencyclidine	ND	J. Posada

Drug Screen/Confirmation

Liver

Bases-GC/NPD &/or MS	Methylphenidate	0.20 ug/g	R. Cabrera
----------------------	-----------------	-----------	------------

hmc 3/5/2020

Coroner Case Number: 2020-00797 Decedent: BRYANT, KOBE BEAN

SPECIMEN SERVICE DRUG RESULT ANALYST

NOTE: AKA John Doe. *May not be Title 17 compliant; analysis performed in singlet due to limited specimen volume.


Legend:		ND	Not Detected	SNS	Specimen Not Suitable
g	Grams	ng/g	Nanograms per Gram	TNP	Test Not Performed
g%	Gram Percent	ng/mL	Nanograms per Milliliter	ug	Micrograms
In c.	Inconclusive	PP	Presumptive Positive	ug/g	Micrograms per Gram
mg	Milligrams	QNS	Quantity Not Sufficient	ug/mL	Micrograms per Milliliter

The alcohol analysis was performed in accordance to California Code of Regulations "Title 17" compliance by a qualified analyst in the Forensic Toxicology Laboratory, Forensic Laboratories Division, County of Los Angeles Department of Medical Examiner - Coroner.

Enzyme-linked immunosorbent assay (ELISA) provides only a preliminary analytical result that is contingent upon a confirmatory test. A "presumptive positive" (PP) signifies a detection of a drug class and must be confirmed by additional testing for true identification and/or quantitation of specific drug(s) present in the specimen.

Per the Department's Evidence Retention Policy, the blood specimen(s) will be retained for one year (minimum) and all other specimens six months (minimum) from Autopsy.

Final Review By:



Sarah Buxton de Quintana
Supervising Criminalist I

Date: 3/2/20

The above results relate only to the items sampled and tested and have been technically and administratively reviewed and are the opinions and conclusions of the analyst noted. The final review has been certified by the noted Toxicologist to ensure that all standard operating procedures were followed as set by the Forensic Toxicology Laboratory, Forensic Sciences Laboratory Division, County of Los Angeles Department of Medical Examiner-Coroner.

m 3/5/2020

A. Crank

CASE REPORT

COUNTY OF LOS ANGELES

DEPARTMENT OF CORONER

1	APPARENT MODE ACCIDENT	CASE NO 2020-00797
	SPECIAL CIRCUMSTANCES	CRYPT SCI

LAST, FIRST MIDDLE DOE, JOHN	AKA	#
--	-----	---

ADDRESS	CITY	STATE	ZIP
---------	------	-------	-----

SEX UNKNOWN	RACE APPEARS	DOB	AGE	HGT in.	WGT lbs.	EYES UNKNOWN	HAIR UNKNOWN	TEETH NO TEETH	FACIAL HAIR BEARD AND MUSTACHE	ID VIEW Yes	CONDITION POOR CONDITION
----------------	--------------	-----	-----	------------	-------------	-----------------	-----------------	-------------------	-----------------------------------	----------------	-----------------------------

MARK TYPE	MARK LOCATION	MARK DESCRIPTION
-----------	---------------	------------------

NEW	ADDRESS SEE CASE NOTES	CITY	STATE	ZIP
-----	----------------------------------	------	-------	-----

RELATIONSHIP	PHONE	NOTIFIED BY BRIAN ELIAS	DATE 1/27/2020	TIME
--------------	-------	-----------------------------------	-------------------	------

SSN	CL ID	STATE CA	PENDING BY
-----	-------	-------------	------------

ID METHOD
FINGERPRINTS FROM DOJ

LA #	MAIN #	CL#	FBI#	MILITARY #	POB
------	--------	-----	------	------------	-----

IDENTIFIED BY NAME (PRINT) DOJ PRINTS	RELATIONSHIP	PHONE	DATE 1/26/2020	TIME 20:20
---	--------------	-------	-------------------	---------------

PLACE OF DEATH / PLACE FOUND MOUNTAIN SIDE	ADDRESS OR LOCATION 4232 LA VIRGENES RD.	CITY CALABASAS	ZIP 91303
--	--	--------------------------	---------------------

PLACE OF INJURY MOUNTAIN SIDE	AT WORK No	DATE 1/26/2020	TIME	LOCATION OR ADDRESS 4232 LA VIRGENES RD., CALABASAS, CA	ZIP 91303
---	---------------	-------------------	------	---	--------------

DCD 1/26/2020	TIME 10:10	FOUND OR PRONOUNCED BY LACFD SMITH
------------------	---------------	--

OTHER AGENCY INV. OFFICER	PHONE	REPORT NO.	NOTIFIED BY	NO
---------------------------	-------	------------	-------------	----

TRANSPORTED BY PEDRO NGAYAN	TO LOS ANGELES FSC	DATE 1/26/2020	TIME 19:25
---------------------------------------	------------------------------	-------------------	---------------

FINGERPRINTS? Yes	CLOTHING No	PARPT No	MORTUARY
MED. EV. No	INVEST. PHOTO # 0	SEAL TYPE	HOSP RPT No
PHYS. EV. No	EVIDENCE LOG No	PROPERTY? No	HOSP CHART No
SUICIDE NOTE No	GSR NO	RCPT. NO.	PF NO.

SYNOPSIS
 THE DECEDENT WAS ONE OF NINE INDIVIDUALS INVOLVED IN A HELICOPTER CRASH ON 01/26/2019. ON 01/26/2019 A SIKORSKY S-76B THAT THE DECEDENT WAS RIDING IN CRASHED INTO MOUNTAINOUS TERRAIN IN THE CITY OF CALABASAS. WEATHER CONDITIONS AT THE TIME OF THE COLLISION WERE REPORTED TO BE FOGGY. THE HELICOPTER APPEARS TO HAVE CRASHED INTO A MOUNTAIN BEFORE MAKING A SMALL SKIP AND COMING TO REST NEAR A HIKING TRAIL. THE TAIL OF THE HELICOPTER WAS LOCATED SOUTH OF THE MAIN BODY OF THE HELICOPTER. VARIOUS AIRCRAFT PARTS WERE STREWN FOR APPROXIMATELY 100 YARDS NORTH OF THE APPARENT MAIN POINT OF IMPACT. THE DECEDENT WAS OBSERVED LYING IN THE DIRT TO THE IMMEDIATE SOUTH OF THE MAIN WRECKAGE OF THE HELICOPTER.

KRISTINA MCGWIRE 547544	<i>K. McGwire</i>	INVESTIGATOR	DATE 1/27/2020	TIME 23:01	REVIEWED BY <i>[Signature]</i>	DATE 1/27/20	TIME 2315
----------------------------	-------------------	--------------	-------------------	---------------	-----------------------------------	-----------------	--------------

FORM #3 NARRATIVE TO FOLLOW?

COUNTY OF LOS ANGELES

CASE REPORT

DEPARTMENT OF CORONER

1	APPARENT MODE ACCIDENT	CASE NO 2020-00797
	SPECIAL CIRCUMSTANCES Celebrity, Media Interest, Multiple Deaths	CRYPT SC1

LAST, FIRST MIDDLE BRYANT, KOBE BEAN	AKA	#
--	-----	---

ADDRESS 3 AVALON VISTA	CITY NEWPORT COAST	STATE CA	ZIP 92657
----------------------------------	------------------------------	--------------------	---------------------

SEX MALE	RACE APPEARS BLACK	DOB 8/23/1978	AGE 41	HGT in.	WGT 178 lbs.	EYES UNKNOWN	HAIR UNKNOWN	TEETH NO TEETH	FACIAL HAIR BEARD AND MUSTACHE	ID VIEW Yes	CONDITION POOR CONDITION
--------------------	------------------------------	-------------------------	------------------	-------------------	------------------------	------------------------	------------------------	--------------------------	--------------------------------	-----------------------	------------------------------------

MARK TYPE	MARK LOCATION	MARK DESCRIPTION
-----------	---------------	------------------

NOX	ADDRESS	CITY	STATE	ZIP
-----	---------	------	-------	-----

RELATIONSHIP	PHONE	NOTIFIED BY CHIEF B. ELIAS	DATE 1/27/2020	TIME
--------------	-------	--------------------------------------	--------------------------	------

SSN	DOB	STATE CA	PENDING BY
-----	-----	--------------------	------------

ID METHOD FINGERPRINTS FROM DOJ

LA #	MAIN #	CITY	REL #	MILITARY #	POB
------	--------	------	-------	------------	-----

IDENTIFIED BY NAME (PRINT) DOJ PRINTS	RELATIONSHIP	PHONE	DATE 1/26/2020	TIME 20:20
---	--------------	-------	--------------------------	----------------------

PLACE OF DEATH / PLACE FOUND MOUNTAIN SIDE	ADDRESS OR LOCATION 4232 LAS VIRGENES RD.	CITY CALABASAS	ZIP 91303
--	---	--------------------------	---------------------

PLACE OF INJURY MOUNTAIN SIDE	AT WORK No	DATE 1/26/2020	TIME	LOCATION OR ADDRESS 4232 LAS VIRGENES RD., CALABASAS, CA	ZIP 91303
---	----------------------	--------------------------	------	--	---------------------

DOB 1/26/2020	TIME 10:10	FOUND OR PRONOUNCED BY LACFD SMITH
-------------------------	----------------------	--

OTHER AGENCY INV. OFFICER	PHONE	REPORT NO.	NOTIFIED BY	NO
---------------------------	-------	------------	-------------	----

TRANSPORTED BY PEDRO NGAYAN	TO LOS ANGELES FSC	DATE 1/26/2020	TIME 19:25
---------------------------------------	------------------------------	--------------------------	----------------------

FINGERPRINTS? Yes	CLOTHING No	PART No	MORTUARY
MED. EV. No	INVEST. PHOTO # 0	SEAL TYPE	HOSP RPT No
PHYS. EV. No	EVIDENCE LOG No	PROPERTY? No	HOSP CHART No
SUICIDE NOTE No	GSR NO	RCPT. NO.	PF NO.

SYNOPSIS
THE DECEDENT WAS ONE OF NINE INDIVIDUALS INVOLVED IN A HELICOPTER CRASH ON 01/26/2019. ON 01/26/2019 A SIKORSKY S-76B THAT THE DECEDENT WAS RIDING IN CRASHED INTO MOUNTAINOUS TERRAIN IN THE CITY OF CALABASAS. WEATHER CONDITIONS AT THE TIME OF THE COLLISION WERE REPORTED TO BE FOGGY. THE HELICOPTER APPEARS TO HAVE CRASHED INTO A MOUNTAIN BEFORE MAKING A SMALL SKIP AND COMING TO REST NEAR A HIKING TRAIL. THE TAIL OF THE HELICOPTER WAS LOCATED SOUTH OF THE MAIN BODY OF THE HELICOPTER. VARIOUS AIRCRAFT PARTS WERE STREWN FOR APPROXIMATELY 100 YARDS NORTH OF THE APPARENT MAIN POINT OF IMPACT. THE DECEDENT WAS OBSERVED LYING IN THE DIRT TO THE IMMEDIATE SOUTH OF THE MAIN WRECKAGE OF THE HELICOPTER.

KRISTINA MCCUIRE 547344 <i>K. McCuire</i>	DATE 1/27/2020	REVIEWED BY LARRY DIETZ <i>Larry Dietz</i>	DATE 1/28/2020
INVESTIGATOR	TIME 23:01		TIME 00:18

FORM #3 NARRATIVE TO FOLLOW?



County of Los Angeles, Department of Coroner
Investigator's Narrative



Case Number: 2020-00797

Decedent: BRYANT, KOBE BEAN

Information Sources:

1. Aircraft Accident Investigation Report, National Transportation Safety Board, Washington D.C. 20594.
2. On scene investigation.

Investigation:

Initial reports indicate that on 01/26/2020 at approximately 0945 hours multiple witnesses called 911 reporting that a helicopter had crashed into the foothills of the Santa Monica mountains above Las Virgenes Road in the City of Calabasas. Deputies from the Los Angeles County Sheriff's Department and personnel from the Los Angeles County Fire Department responded to the scene. Upon arrival to the scene nine decedents were located and pronounced dead at 1010 hours by Los Angeles County Fire Department personnel.

On 01/26/2020 at 1338 hours Officer Rodriguez from the Los Angeles County Sheriff's Department-Homicide Bureau called to report this multi-decedent helicopter crash fatality to Investigator Jeffrey Guilmette at the Los Angeles County Department of the Medical Examiner-Coroner. I was assigned this Special Operations Response Team (SORT) field case at 1400 hours by Acting Supervisor Anthony Lopez. I arrived on scene at approximately 1620 hours and cleared the scene at approximately 1930 hours. On 01/26/2020 the following SORT team members responded to the scene for a coordinated search and decedent removal:

M. Lee #605743, L. Cervantes #639654, P. Ngayan #531611, B. Kim #602036, E. Napoles #465129, M. Gutierrez #479704, R. Estrada #486093, R. Gonzalez #503064, J. Fallot #644073.

On 01/27/2020 at approximately 0630 hours I returned to the scene and cleared the scene at approximately 1600 hours. On 01/27/2020 the following SORT Team Members returned to the scene for a continued coordinated search and decedent removal:

M. Lee #605743, L. Cervantes #639654, P. Ngayan #531611, B. Kim #602036, E. Napoles #465129, M. Gutierrez #479704, R. Estrada #486093, R. Gonzalez #503064, J. Fallot #644073. F. Fernandez #486349, M. Molina #421452.

Forensic Attendant P. Ngayan transported all decedents to the Forensic Science Center.

Also present at the scene were Chief B. Elias, Captain E. Tauscher and Dr. J. Lucas.

Location:

Place of Injury/Death: Mountainside, 4232 Las Virgenes Road, Calabasas, CA 91303.

Informant/Witness Statements:

A review of a report issued by the National Transportation Safety Board revealed the following information:

On 01/26/2020 at 0945 hours a Sikorsky S-76B helicopter, N72EX, collided with hilly terrain near the city of Calabasas. The helicopter held 8 passengers and a pilot who were all killed on impact. The Sikorsky was in an 8-passenger seat configuration with two pilot stations up front and eight passengers in the rear, separated by a bulkhead with sliding acrylic windows. Passenger seating was 2 four-occupant divans, one facing forward and the other rearward. A main impact crater measuring 24 feet by 15 feet in diameter was observed with the main wreckage noted to be about 127 feet along a 347° true bearing from the impact crater. The helicopter was destroyed by impact forces and fire with the entire fuselage/cabin and both engines subjected to a post-crash fire.

**County of Los Angeles, Department of Coroner
Investigator's Narrative**

Case Number: 2020-00797

Decedent: BRYANT, KOBE BEAN

Scene Description:

The scene is mountainous, vegetation covered terrain located east of 4232 Las Virgenes Road in the City of Calabasas. Due to the size of the scene a stake was placed at a central point located just north of what appears to be the main fuselage. The GPS coordinates of the stake were 34°8'14" N and 118°41'33" W. What appeared to be an initial point of impact designated by a disturbance to the soil and vegetation and various helicopter parts, personal property and human remains were located approximately 120 feet south of the designated central stake. What appeared to be a white and blue helicopter tail piece printed with "Sikorsky" was located down a western slope from the initial point of impact. The helicopter wreckage, personal property and human remains were spread in a cone shape across the area starting at the initial point of impact and spreading toward the north stopping at the north side of a ravine. A designated hiking/bicycle path was located surrounding the scene.

Evidence:

No evidence was collected for this case.

Body Examination:

The decedent is an adult Black male I observed lying on the ground just south of the main fuselage in the above described scene. He was wearing black pants, a sweater, underwear and a shirt. He has black hair, an unknown eye color and natural teeth. Upon external examination I observed significant trauma to his head, right arm and lower body.

Identification:

The decedent was positively identified as Kobe Bean Bryant (DOB: 08/23/1978) via Department of Justice fingerprints.

Next of Kin Notification:

Chief B. Elias provided telephonic notification of the decedent's death to [REDACTED] decedent.

Tissue Donation:

Not addressed.

Autopsy Notification:

No exam request was noted.

KRISTINA MCGUIRE
#547544

SUPERVISOR

02/13/2020

Date of Report